
GALERÍA DE IMÁGENES
LESIONES CUTÁNEAS VULVARES
VULVAR SKIN LESIONS

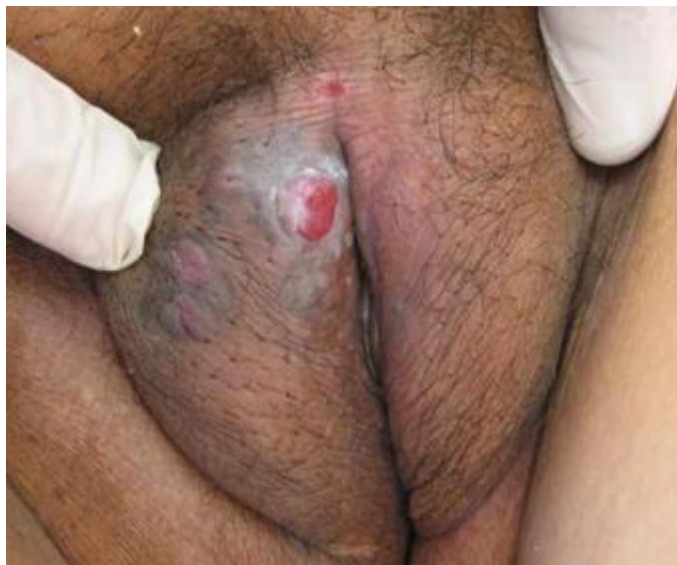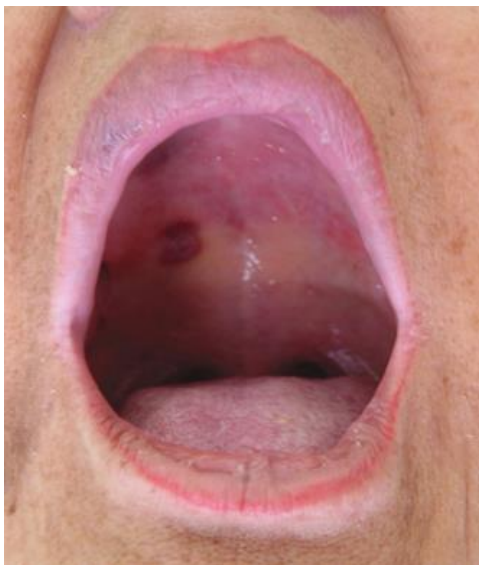Dra. Alejandra Isaac Montero¹ y Dra. Claudia Alejandra Capozzi Cárdenas¹

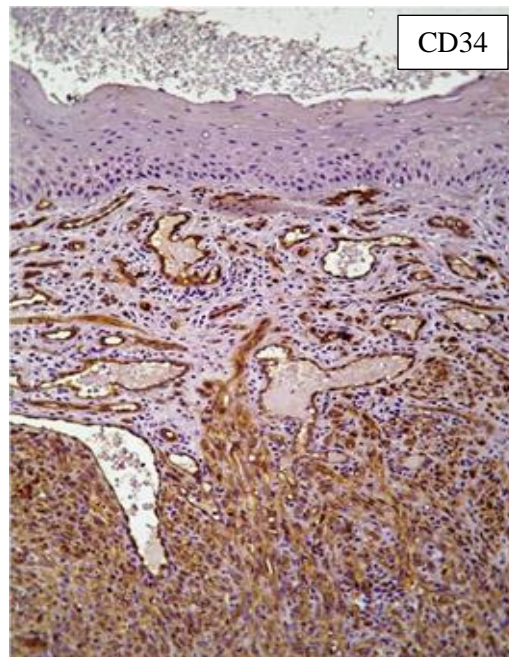
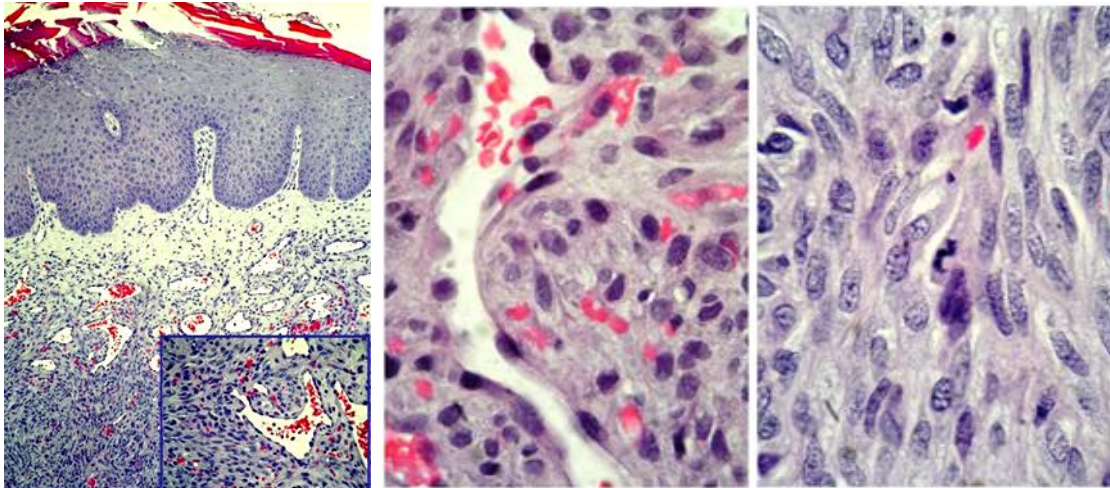
¹ Servicio de Anatomía Patológica del Complejo Hospitalario Universitario de Cartagena, Región de Murcia (España).

Recibido: 17 de Julio, 2023 **Aceptado:** 22 de Diciembre, 2023 **Publicado:** 19 de Enero, 2024

DOI: <https://doi.org/10.17811/ap.v4i1.20844>

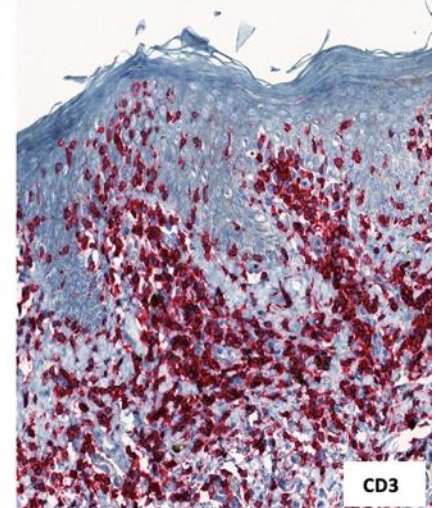
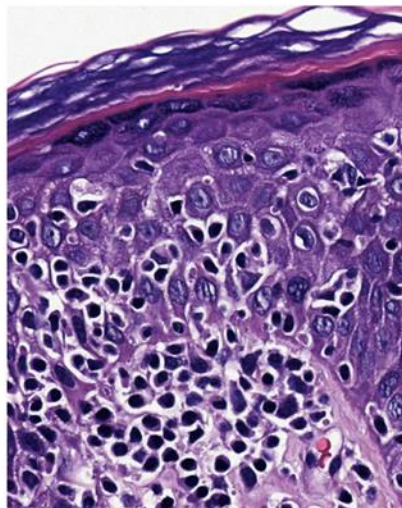
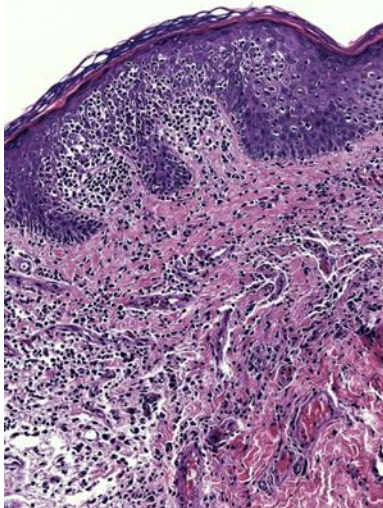
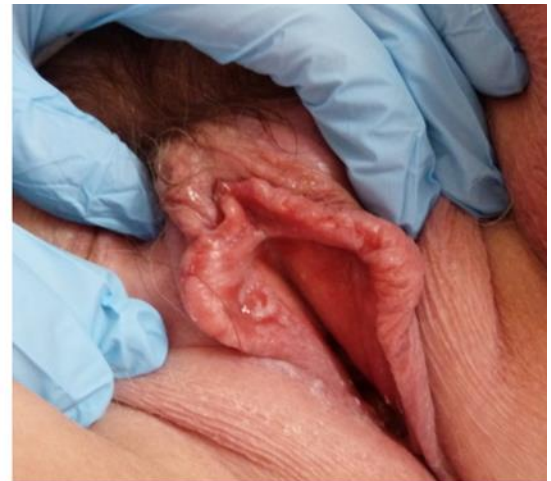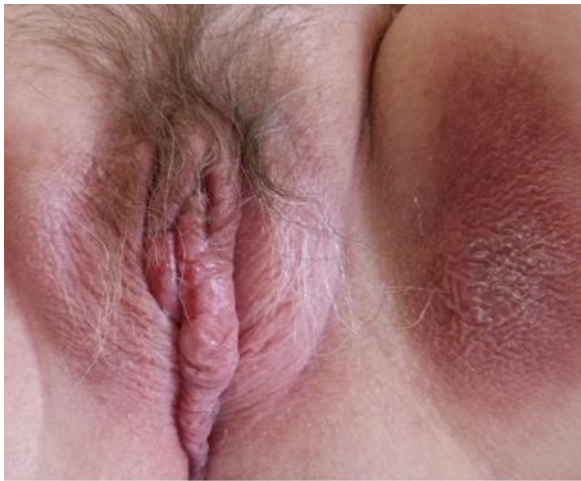- 1. PACIENTE DE 48 AÑOS CON SIDA ESTADIO C3, MAL CONTROLADA CON AFECTACIÓN DE MUCOSA VULVAR Y ORAL POR SARCOMA DE KAPOSI (HHV8+).**
48 year old patient with poorly controlled stage C3 AIDS with vulvar and oral mucosa infection by kaposi sarcoma (HHV8+).





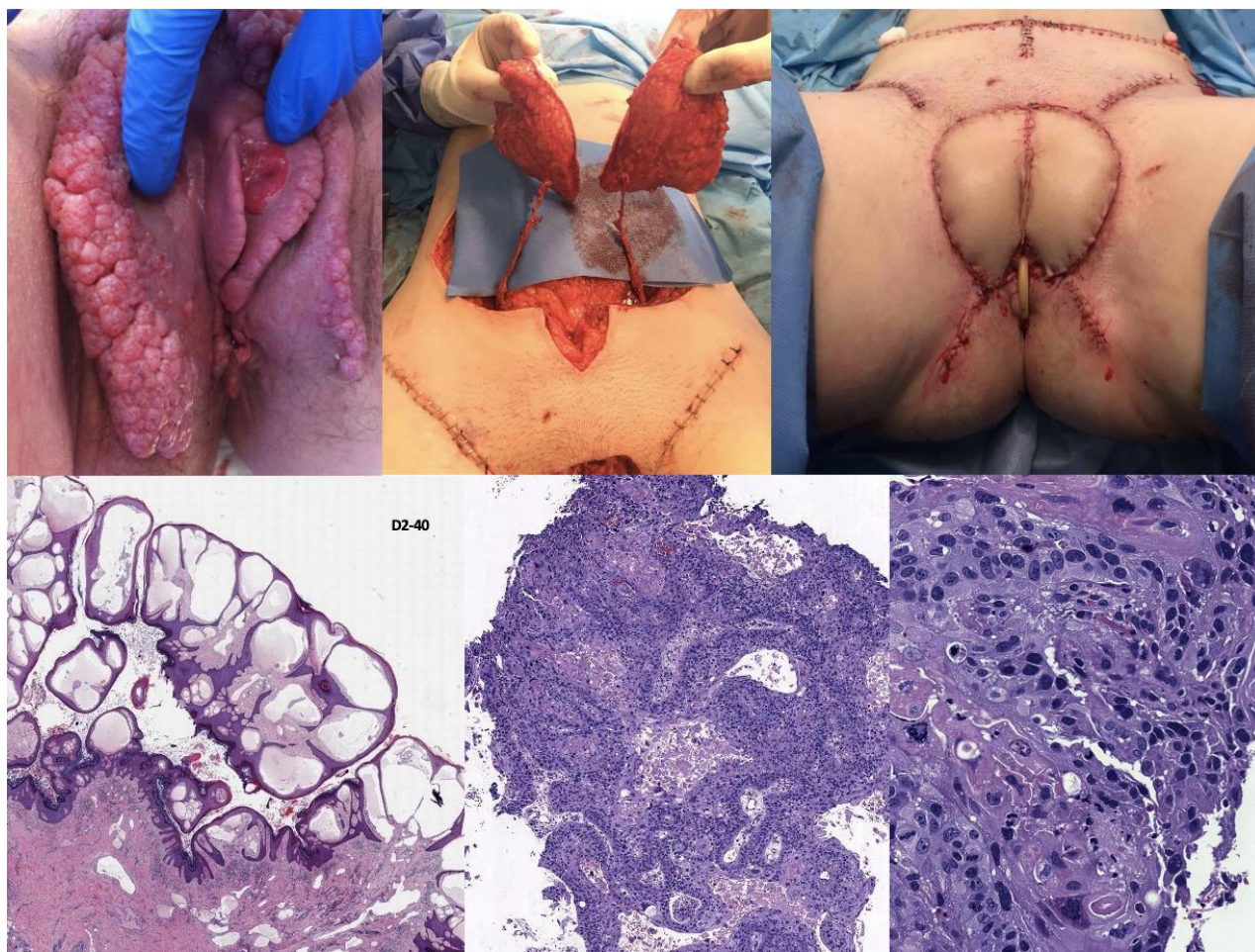
2. PACIENTE DE 50 AÑOS CON LESIÓN ERITEMATOSA Y ULCERADA A NIVEL VULVAR Y LESIÓN ECCEMATOSA EN MUSLO, AMBAS REFRACTARIAS AL TRATAMIENTO, QUE SE CORRESPONDEN CON EL DIAGNÓSTICO DE MICOSIS FUNGOIDES.

50 year old patient with erythematous and ulcerated lesion at the vulvar region and eczematous lesion on the thigh, both refractory to treatment, which correspond to the diagnosis of fungoid mycosis.



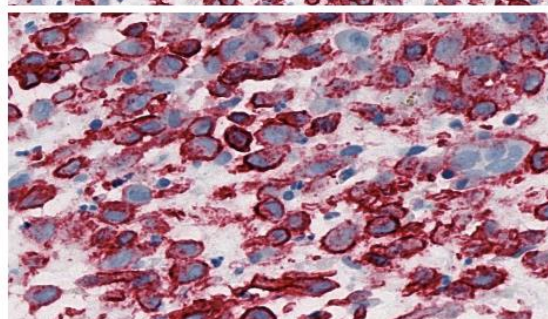
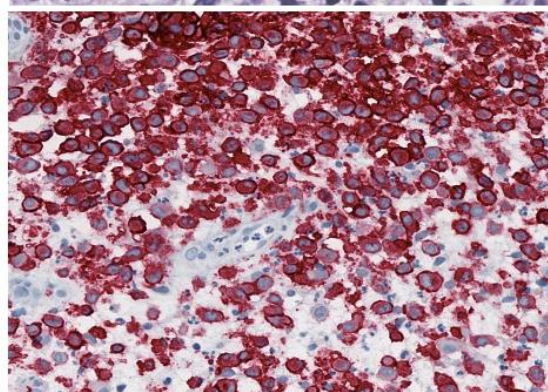
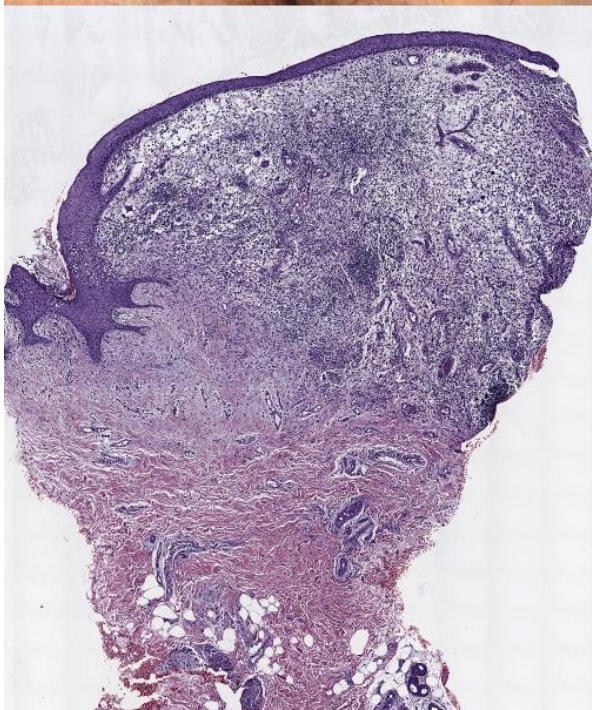
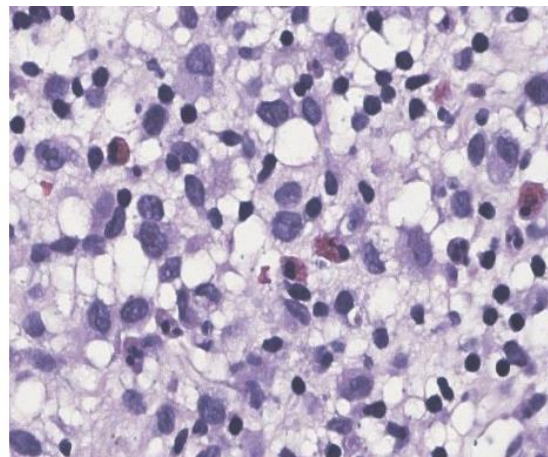
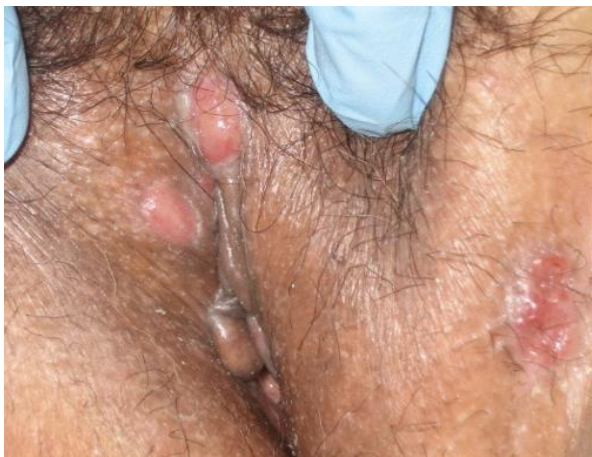3-PACIENTE DE 47 AÑOS CON AP: LINFEDEMA CRÓNICO EN MIEMBROS INFERIORES, PRUEBAS TREPONÉMICAS + Y REAGÍNICAS NEGATIVAS, CONSUMO COCAÍNA Y ENOLISMO MODERADO CON UN CARCINOMA QUERATINIZANTE DE CÉLULAS ESCAMOSAS SOBRE CONDILOMATOSIS FLORIDA ASOCIADA A LINFANGIOMA CIRCUNSCRITO CON RECONSTRUCCIÓN VULVOPERINEAL.

47 year old patient with chronic lymphedema in lower limbs, treponemic test + and reagin tests negative, cocaine consumption and moderate enolism with a keratinizing squamous cell carcinoma on condylomatosis associated with circumscribed lymphangioma with reconstruction vulvoperineal.



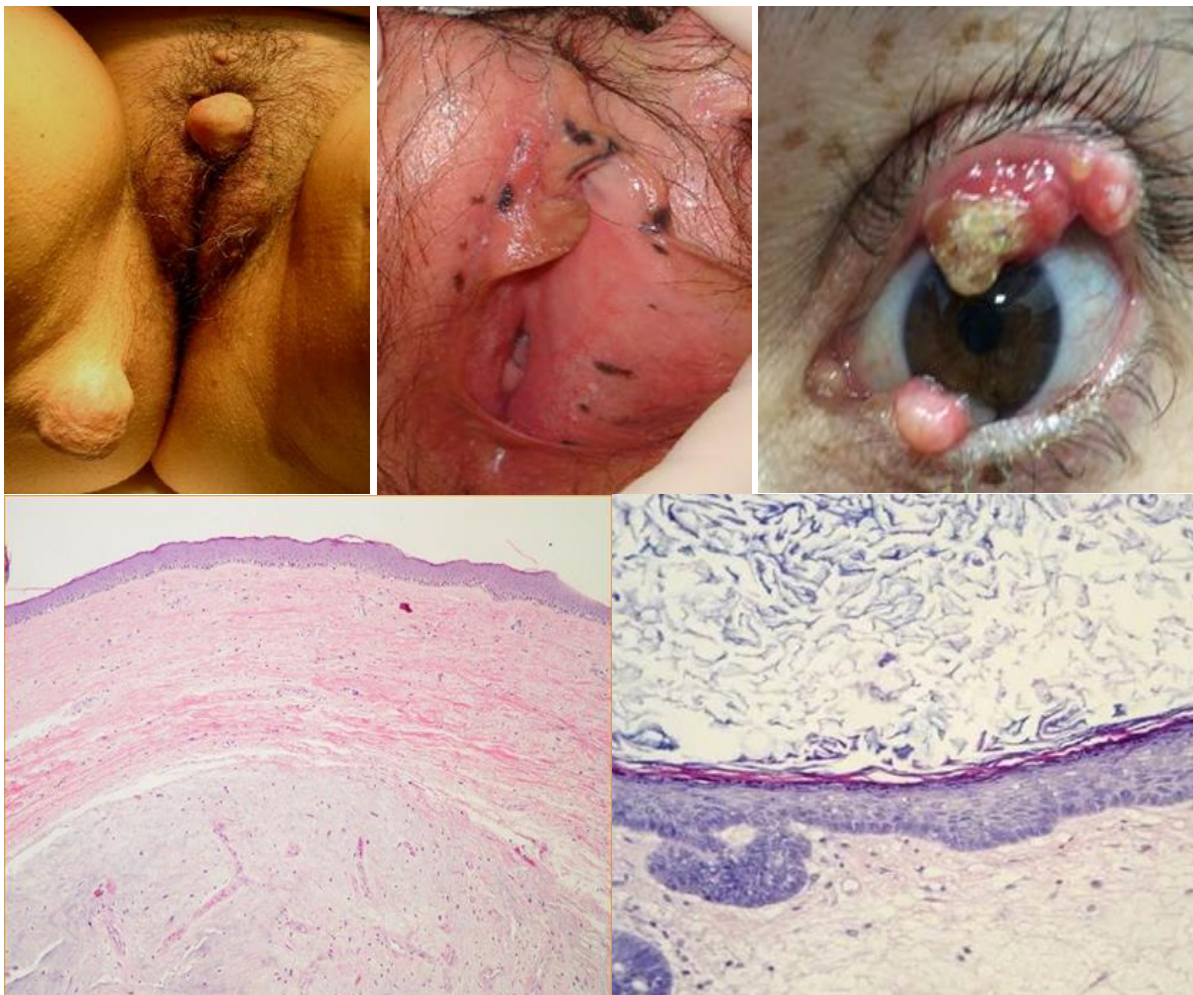
4-LESIONES PRURIGINOSAS Y DOLOROSAS DE 6 MESES DE EVOLUCIÓN, LOCALIZADAS EN INGLES Y VULVA, QUE CORRESPONDEN A UNA HISTIOCITOSIS DE CÉLULAS DE LANGERHANS (CD1+ Y LANGERINA +).

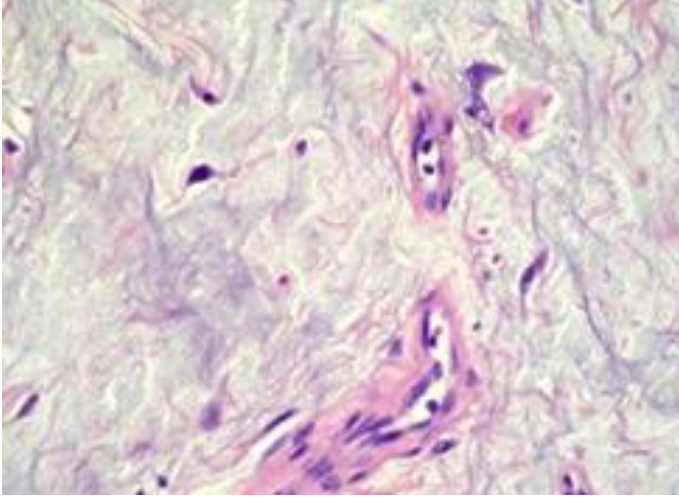
Pruriginous and painful lesions of 6 months of evolution, located in the groin and vulva, which correspond to a histiocytosis of Langerhans cells (CD1+ and langerin +).



5-MUJER DE 37 AÑOS CON SÍNDROME DE CARNEY QUE PRESENTA MÚLTIPLES MIXOMAS CUTÁNEOS Y CARDÍACO, QUISTES EPIDERMOIDES, TRASTORNO BIPOLAR Y FAMILIARES CON LÉNTIGOS/EFÉLIDES.

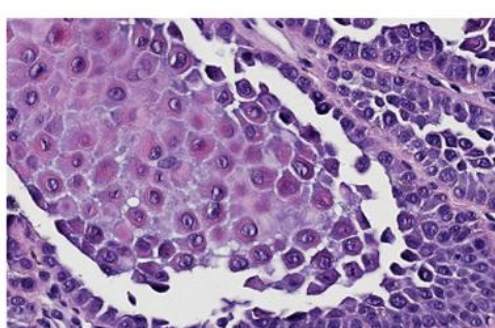
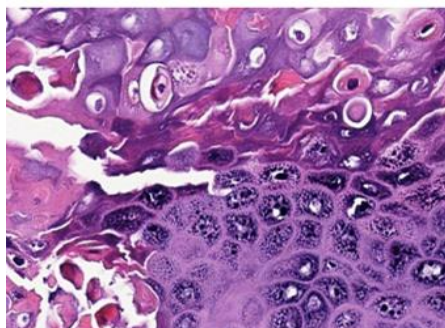
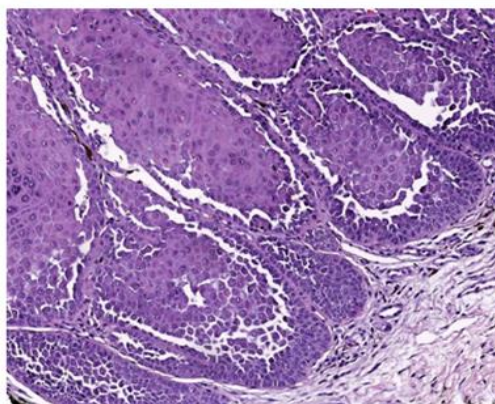
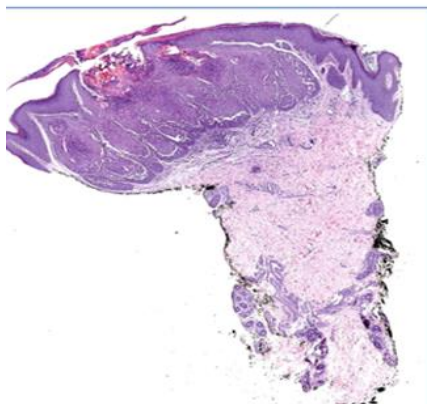
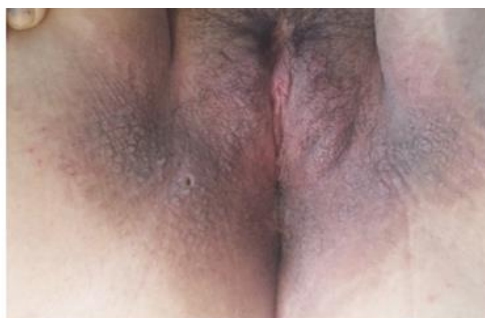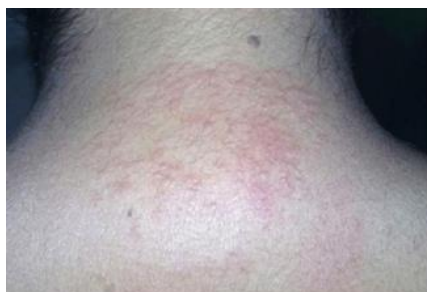37-year-old woman with carney syndrome presenting multiple skin and cardiac mixomas, epidermoid cysts, bipolar disorder and relatives with lentigos/efelids.





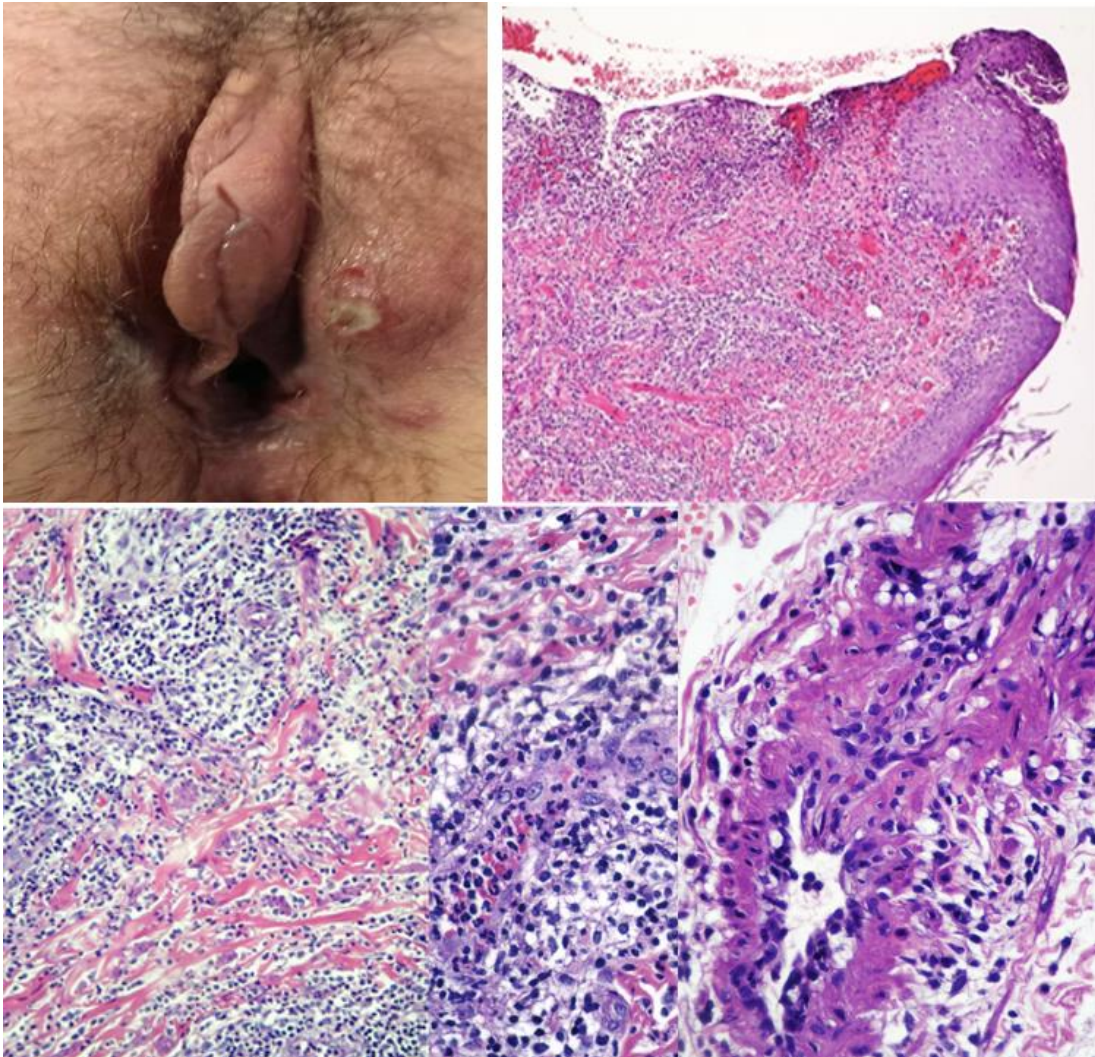
6-MUJER DE 24 AÑOS, CON ANTECEDENTES DE CONDILOMATOSIS VULVAR (HPV66) Y HERPES GENITAL (HSV1,) ASOCIADA A ENFERMEDAD DE DARIER, QUE PRESENTA LESIONES VESICULADAS, BRILLANTES Y DESCAMATIVAS EN CUELLO Y UNA PLACA DE ASPECTO EMPEDRADO, SIMÉTRICA Y DE COLOR MARRÓN A NIVEL VULVAR.

A 24-year-old woman, with a history of vulvar condylomatosis (HPV 66) and genital herpes (HSV1) associated with Darier's disease, presents with vesiculated, shiny and scaly lesions on the neck and a cobblestone-looking, symmetrical, brown plaque at the same vulvar level.



7- MUJER DE 23 AÑOS, CON ANTECEDENTES DE FARINGITIS ASOCIADOS A ÚLCERAS ORALES Y VULVARES, QUE PRESENTA NUEVO EPISODIO DE ÚLCERAS VULVARES DOLOROSAS CON DIAGNÓSTICO DE VASCULITIS LINFOCITARIA COMPATIBLE CON ENFERMEDAD DE BEHÇET.

A 23-year-old woman, with a history of pharyngitis associated with oral and vulvar ulcers, presented with a new episode of painful vulvar ulcers with a diagnosis of lymphocytic vasculitis compatible with Behçet's Disease.



COMO CITAR:

Isaac Montero, A., & Capozzi Cárdenas, C. A. Lesiones cutáneas vulvares. *Archivos De Patología*, 4(1). <https://doi.org/10.17811/ap.v4i1.20844>

